



## Giant arachnoidal cyst

Tereza GABELIĆ<sup>1</sup>, Nataša KLEPAC<sup>1</sup>, Zdenko MUBRIN<sup>1</sup>, David OZRETIĆ<sup>3</sup> and Mario HABEK<sup>1,2</sup>

<sup>1</sup>University Department of Neurology, Zagreb Medical School and <sup>2</sup>University Hospital Center Zagreb, Croatia;

<sup>3</sup>University Department of Radiology, University Hospital Center Zagreb, Croatia

*Key words:* Arachnoid cyst; dementia.

An 81-year-old man with a 1-year history of dementia was admitted because of development of walking difficulties and urinary incontinence. Neurological examination revealed skull bulging on the left, gait with shuffling steps and start hesitation. On MMSE he scored 13 points.

Brain MRI showed a giant congenital supratentorial arachnoidal cyst, Galassi III. There was a compressive effect on left frontal, temporal and parietal lobes with a 12 mm right shift of the midline and dilatation of the right lateral ventricle. On FLAIR images there were periventricular hyperintensities consistent with CSF transudation (Fig. 1).

In spite of these impressive MRI findings, there was no motor, sensory or coordination system impairment. The patient and his family refused any neurosurgical intervention.

Arachnoid cysts very rarely exert a mass effect and in most instances there is no correlation between their size and symptom severity (Sommer and Smit, 1997).

### REFERENCES

Sommer IE, Smit LM. Congenital supratentorial arachnoidal and giant cysts in children: a clinical study with arguments for a conservative approach. *Childs Nerv Syst.* 1997;13:8-12.

Mario Habek, M.D.,  
University Department of Neurology,  
Zagreb School of Medicine and University  
Hospital Center,  
Kišpatičeva 12,  
HR-10000 Zagreb (Croatia).  
E-mail: mhabek@mef.hr

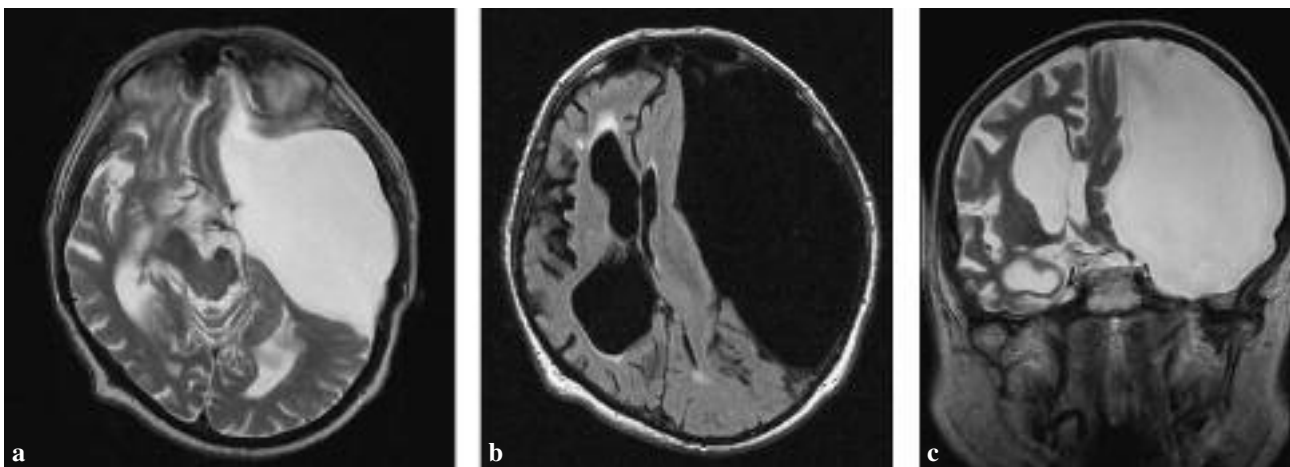


FIG. 1. — Brain MRI showing the giant subarachnoid cyst (7.4 × 18.2 × 12.8 cm) on the left and overlying skull asymmetry. a) axial T2; b) axial FLAIR and c) coronal T2 sequence.